



**PATIENT**

Prince Yulico

**SPECIES**

Canine

**BREED**

Japanese Chin

**SEX**

Male Neutered

**AGE**

14 years

**WEIGHT**

7.2lbs

**INTERPRETED BY**

Maggie Machen Lamy,  
DVM, DACVIM  
(Cardiology)

**IMAGING PERFORMED BY**

Travis Cerf, DVM

**HOSPITAL NAME**

Vertinary Center of  
Hardyston

**REFERRING VET**

Dr. Cerf

**INVOICE**

31987

**DATE**

7/28/23

**PRESENTING CLINICAL SIGNS**

History: Grade 4/6 heart murmur.  
-Current medications: Pimobendan 1.5mg PO BID.  
-Abnormal PE/Chem/CBC/UA Results: Hypoalbuminemia (2.0)

**ECHOCARDIOGRAM FINDINGS**

2D, m-mode, color flow and doppler imaging is available. Mild diffuse thickening of mitral valve leaflets with minimal prolapse into the left atrial lumen. Mild eccentric mitral regurgitation with mild left atrial dilation. Normal MR velocity. Normal LV diameter with adequate myocardial function. The tricuspid valve appears normal with mild tricuspid regurgitation. Normal right atrial and ventricular diameter and morphology indicating no overt evidence of pulmonary arterial hypertension. The pulmonic and aortic valves are normal in morphology and mobility. Normal pulmonic and aortic outflow velocities with laminar flow. No obvious aortic or pulmonic insufficiency. No pericardial or pleural effusion noted. No obvious cardiac masses.

**CARDIAC CHART**

| CANINE CARDIAC PARAMETERS  | MR VMAX (m/s) | TR VMAX (m/s) | LA/AO (Boon method) | LA/AO (Heart Base; Swe) | FS (%)                          | EF (%)                                   | EPSS (cm)                                |
|--|---------------|---------------|---------------------|-------------------------|---------------------------------|--|--|
| NORMAL PARAMETER   | 4.5-5.5       | <2.7          | 1.3                 | <1.6                    | 28-40                           | 40-100                                   | <0.6                                     |
| PATIENT  | 5.2           | NM            | NM                  | 1.4                     | 54                              | 90                                       | NM                                       |
| CANINE CARDIAC PARAMETERS  | HR (BPM)      | AV VMAX (m/s) | PV MAX (m/s)        | BODY WEIGHT (kg)        | LA 2D short axis Base view (cm) | LVIDd Avg; 2D and m-mode short axis (cm) | LVIDs Avg; 2D and m-mode short axis (cm) |
| NORMAL PARAMETER   | 50-100        | 0.7-1.7       | 0.7-1.6             | BELOW                   | BELOW                           | BELOW                                    | BELOW                                    |
| PATIENT  | NM            | NM            | 0.8                 | 3.3                     | 1.6                             | 2.4                                      | 1.1                                      |
| *Normal chamber parameters expressed as a mean value (SD)  |               |               |                     |                         |                                 |  |  |
| <b>BODY WEIGHT DEPENDENT PARAMETERS</b>  |               |               |                     |                         |                                 |  |  |
| *Note: All measurements based upon multi-modal images and methods. An average value is reported. |               |               |                     |                         |                                 |  |  |
|  |               |               |                     | 3                       | 1.27 (5.3)                      | 2.46 (2.46)                              | 1.36 (5.5)                               |
|  |               |               |                     | 5                       | 1.40 (4.5)                      | 2.74 (5.2)                               | 1.60 (4.7)                               |
|  |               |               |                     | 10                      | 1.50 (3.8)                      | 3.27 (3.5)                               | 2.06 (3.1)                               |
|  |               |               |                     | 15                      | 1.83 (2.0)                      | 3.71 (2.4)                               | 2.43 (2.1)                               |
|  |               |               |                     | 20                      | 2.02 (1.9)                      | 4.14 (2.2)                               | 2.80 (2.0)                               |
|  |               |               |                     | 25                      | 2.18 (2.4)                      | 4.48 (2.9)                               | 3.10 (2.5)                               |
|  |               |               |                     | 30                      | 2.33 (3.3)                      | 4.83 (3.9)                               | 3.39 (3.4)                               |
|  |               |               |                     | 35                      | 2.48 (4.3)                      | 5.17 (5.0)                               | 3.69 (4.5)                               |
|  |               |               |                     | 40                      | 2.62 (5.2)                      | 5.48 (6.1)                               | 3.96 (5.4)                               |
|  |               |               |                     | 50                      | 2.88 (7.1)                      | 6.07 (8.3)                               | 4.46 (7.4)                               |

**INTERPRETATION OF THE FINDINGS & FURTHER RECOMMENDATIONS**

Chronic degenerative valve disease causing mild mitral and tricuspid regurgitation. Lack of significant left atrial enlargement indicates the current risk for complication is low. No concurrent issues such as systolic dysfunction or pulmonary hypertension are noted in this study.

Given these findings, no cardiac medications are indicated. That being said, Pimobendan may have decreased left heart dimensions. Depending on chronicity (i.e., if has been administered for >1 week), the safest thing to do is continue the medication. Otherwise, discontinue going forward. Assessment of progression in the future will help predict long term prognosis, which is



**PATIENT**

Prince Yulico

highly variable at this stage (B1). Omega fatty acid supplementation and mild salt restriction may be of some long-term benefit. Monitor for development of a cough, labored breathing, exercise intolerance or collapse episodes.

**SPECIES**

Canine

Anesthetic risk is considered mild if needed. Cardiac protective drug choices (opioid/benzodiazepine premedication, propofol or alfaxalone induction, isoflurane gas) are recommended. Pre-oxygenate for 5-10 minutes prior to induction. Monitor for arrhythmias, hypotension, and hypoxia both intra and post-operatively and intervene as necessary. Mild IV fluid restriction is recommended to avoid fluid overload. Avoid heart rate stimulating drugs such as atropine unless clinically indicated.

**BREED**

Japanese Chin

**SEX**

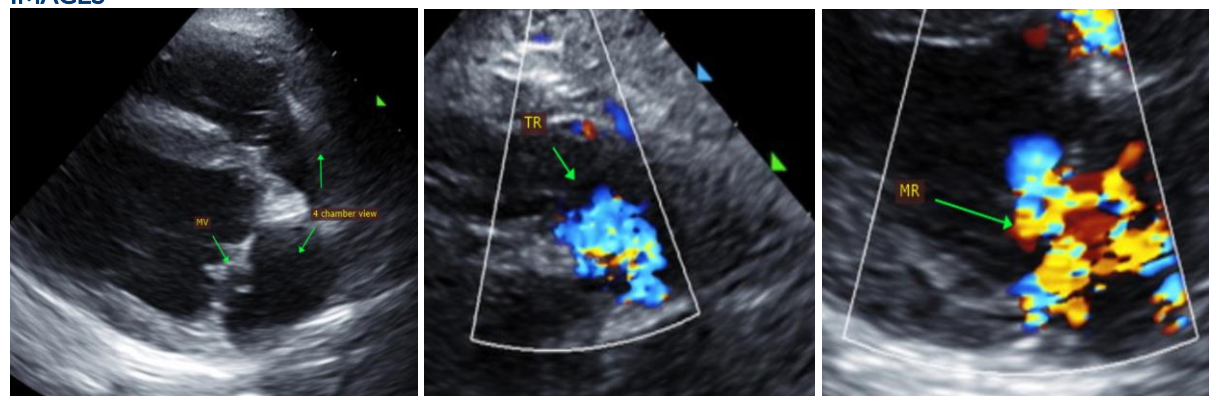
Male Neutered

Recommend conservative monitoring with a recheck echocardiogram in 6 months, sooner if any development of clinical signs.

**AGE**

14 years

**IMAGES**



**WEIGHT**

7.2lbs

**INTERPRETED BY**

Maggie Machen Lamy, DVM, DACVIM (Cardiology)

The information and recommendations provided are based on the images presented by the referring veterinarian. No evaluation can be communicated regarding pathology that was not visible in the image/video clips provided.

**IMAGING PERFORMED BY**

Travis Cerf, DVM

Thank you for this referral. This report was generated using transcription software, and minor dictation errors may be present. If the clinical or image interpretation does not parallel your findings or if I can be of any further assistance, please contact me.

**HOSPITAL NAME**

Vertinary Center of Hardyston

**Maggie Machen Lamy, DVM**  
Diplomate of the American College of Veterinary Internal Medicine (Cardiology)  
info@sonopath.com

**REFERRING VET**

Dr. Cerf

**INVOICE**

31987

**DATE**

7/28/23



**PATIENT**

Prince Yulico

**SPECIES**

Canine

**BREED**

Japanese Chin

**SEX**

Male Neutered

**AGE**

14 years

**WEIGHT**

7.2lbs

**INTERPRETED BY**

Maggie Machen Lamy,  
DVM, DACVIM  
(Cardiology)

**IMAGING  
PERFORMED BY**

Travis Cerf, DVM

**HOSPITAL NAME**

Vertinary Center of  
Hardyston

**REFERRING VET**

Dr. Cerf

**INVOICE**

31987

**DATE**

7/28/23